



# Polyethylene for hip resurfacing—worth a second look

James W. Pritchett

Seattle, WA, USA

Correspondence to: James W. Pritchett, MD. 901 Boren Ave., Suite 711, Seattle, WA 98104, USA. Email: bonerecon@aol.com.

**Background:** In the 1970s and 1980s, hip resurfacing was largely unsuccessful, due to impingement, wear, and component loosening. Today, the availability of better technique and highly cross-linked polyethylene avoids the early causes of failure and provides a successful solution to younger, active patients with advanced osteoarthritis.

**Methods:** The author reviewed the results of 2,154 hip resurfacing arthroplasties he performed over a 21-year period. The procedures used a cementless titanium metal-backed acetabular implant and highly cross-linked polyethylene liner.

**Results:** At a mean follow-up period of 9.5 years (range, 5-21 years), the Kaplan-Meier survivorship was 97.5%, the mean Harris Hip Score was 97, and the UCLA activity score was 8. There were 32 deaths unrelated to the procedure and 35 patients were lost to follow-up. Complications leading to revision included femoral loosening (n=9), infection (n=3), femoral neck fracture (n=12), and these were revised successfully to total hip replacement. Another five patients underwent revision resurfacing for acetabular loosening. There was no evidence of wear through of the polyethylene and examination of retrieved polyethylene components showed a low wear rate from 0.003 to 0.07 mm per year.

**Conclusions:** Hip resurfacing today has proven to be a successful procedure with results as good as or better survivorship than total hip replacement and better function. It is a reliable procedure that meets the physical demands of younger, active patients.

**Keywords:** Hip resurfacing; highly cross-linked polyethylene

Received: 12 November 2019; Accepted: 11 December 2019; Published: 15 April

2020. doi: 10.21037/aoj.2019.12.09

View this article at: <http://dx.doi.org/10.21037/aoj.2019.12.09>

## Introduction

### *Evolution of polyethylene for hip resurfacing*

It is easy to equate the concerns with metal-on-metal arthroplasty and the concept of hip resurfacing. Hip resurfacing and metal-on-metal are not synonymous. The polymers polyethylene, polyurethane, polytetrafluoroethylene, polyester, and polyoxymethylene have all been used for implant arthroplasty of the hip. Polyethylene has been used most commonly, because the other polymers did not have the necessary resistance to wear in their early preparations. The large diameter of the articulation necessary for hip resurfacing is an inherently difficult design challenge. It has taken many years to produce thin wear-resistant polyethylene. Loosening, wear, and impingement were all significant failure issues in

early cases. The results of hip resurfacing in the 1970s and 1980s were generally poor and hip resurfacing was largely abandoned by the mid-1980s (1-6). The legacy of the early failures was a distrust of the hip resurfacing concept. This was similar to the skepticism about metal-on-metal resurfacing today (7-10).

The failure of early polyethylene resurfacing procedures was a consequence of poor materials, poor implant design, inadequate instrumentation, and imprecise surgical technique. Failure is not inherent with the hip resurfacing procedure itself. The concept of hip resurfacing is sound, as it preserves a more normal transmission of forces across the joint. The retention of bone and avoidance of an intramedullary implant are attractive features. Admittedly, hip resurfacing is much more difficult to perform. Hip resurfacing has not been embraced by most orthopedic

surgeons. Hip resurfacing patients are younger and more demanding (11,12).

Preserving the large femoral head makes surgical exposure of the acetabulum difficult. There is a significant exposure advantage in favor of total hip replacement. Typically, there is more deformity present in resurfacing candidates, as they are much more likely to have femoral acetabular impingement and underlying dysplasia because their advanced arthritis occurred at a younger age. The bone preparation during resurfacing is demanding and unforgiving with respect to the fit of the prosthesis to bone. Typically, there is just one implant size appropriate for each patient. The size of the femoral head determines the acetabular implant to be used.

Conventional polyethylene was vulnerable to wear (1,13,14). It was uncertain if efforts to improve polyethylene would be successful, so attention was turned to improving the wear resistance of the femoral component. Cobalt chromium replaced stainless steel. Ceramics either as a fully ceramic femoral component or ceramic-coated titanium came next and were improvements (15). Fully ceramic resurfacing ensembles have been used several times but squeaking and an occasional fracture have been limiting factors. Delta ceramics have been suggested as a solution, but stress shielding has been an issue (16,17). Metal-on-metal has been used widely but adverse reactions to metal wear debris have been the concern (3,18,19).

Improvement of the acetabular bearing was challenging. Initial trials using polyurethane were promising (18,20). The widespread acceptance of polyethylene, however, made it the most attractive candidate material. Five well-accepted assumptions had to be overcome and solved to use polyethylene for hip resurfacing: (I) conventional teaching suggested the minimal polyethylene thickness must be 6 mm (21). Most implants have used much thicker dimensions. Manufacturers, the Food and Drug Administration, and surgeons required relatively thick polyethylene (22); (II) it was assumed that the large capacity of the polyethylene would have unacceptable volumetric wear leading to early failure (23); (III) deformation of the thin polyethylene wear would lead to failure; (IV) impingement would result in pain and ultimate failure given the necessarily larger femoral neck compared to total hip replacement; (V) polyethylene acetabular components must be thicker or larger and, therefore, possibly less bone conserving.

The cross-linking of polyethylene has been a significant advance for all implant arthroplasty procedures. With cross-linked polyethylene, acetabular implants with a capacity of up to 44 mm and greater have been shown to provide the necessary resistance to wear and are available commonly for total hip replacement. Also, cross-linked polyethylene with a thickness of 3.6-4.0 mm has been shown to be safe and implants with this dimension have been in clinical use for many years for both total hip replacement and

resurfacing (18,24-26). With cross-linked polyethylene, thicknesses between 4.0 and 5.0 mm are now routine offerings for total hip replacement. However, impingement can be an issue causing failure with highly cross-linked polyethylene. The polyethylene must be fully supported by the metal backing and not extend beyond the rim as it might in some implants (26,27). The necessarily thin polyethylene with its thin metal backing deforms with surgical implantation and this must be managed carefully. Bone preservation is of paramount importance during hip resurfacing surgery.

The first use of highly cross-linked polyethylene for hip resurfacing surgery immediately followed its introduction for total hip replacement in 1998. Custom implants, total hip polyethylene implants repurposed for hip resurfacing, and specific polyethylene resurfacing implants have been used successfully (2,15,27).

### *Specific design rationale*

There are many valleys of death for good ideas. Conventional wisdom required an incremental approach to innovating the acetabular component for hip resurfacing. Metal-on-metal and ceramic-on-ceramic implants are 6 mm thick. The critical dimension is the last reaming of the acetabulum compared to the last reaming of the femoral head; this should be not more than 10 mm (28). An acetabular component using polyethylene of this dimension is possible. There are circumstances in which there is abundant bone available but it is important to preserve at least 5 mm of medial and anterior walls for most patients. Acetabular preparation is of paramount importance in hip resurfacing.

It is possible to safely make acetabular implants with 4 mm of polyethylene, 2 mm of metal backing, and 1 mm of porous coating (29,30) (*Figure 1*). This ensemble still can have an effective polyethylene liner locking mechanism. If the construct were any thinner it would need to be one piece, as it could not accept a locking mechanism for the polyethylene liner. A two-piece implant allows the use of a central threaded impactor which affords better visualization during insertion. Impactors for one-piece implants can

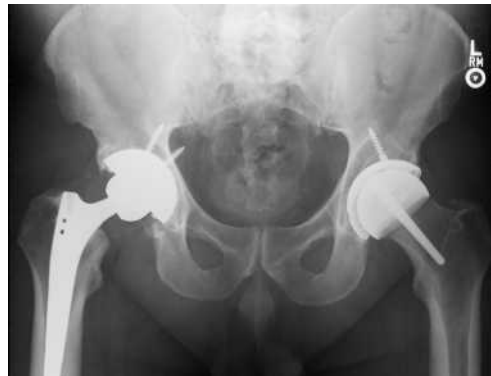

**Figure 1** The resurfacing implants used were two-piece acetabular components, consisting of a porous titanium shell and a highly cross-linked polyethylene liner. The components are porous coated.

impede visualization and or require a more complex inserter (27). Also, a two-piece implant allows for independent polyethylene exchange and for supplemental screw fixation if necessary.

An important advance has been the understanding of the importance of managing the deformation of thin components. Acetabular component deformation has been a significant reason for component failure when using two-piece acetabular constructs with unforgiving metal or ceramic inserts and, possibly, with thin polyethylene. The metal shell deforms against the acetabular bone prepared by the under-reaming necessary to secure a firm press fit (31). Imperfect fit of the metal or ceramic liner can lead to wear debris generation and failure. Thin polyethylene inserts and thin titanium shells also deform during insertion. Stable liner capture by the locking mechanism is critical to the long-term success of the prosthesis. Also, there have been independent concerns about the potential adverse effect of component osseointegration from strain with shell deformation during insertion. These concerns have been proven to be insignificant and osseointegration occurs reliably with under reaming (31).

With correct insertion tools, shell insertion and intraoperative liner engagement have been proven safe. Long-term studies including retrieval data have shown that thin components are successful (22,24). It is possible to under-ream the acetabular component by 3 mm and still be able to insert and assemble the two-piece prosthesis

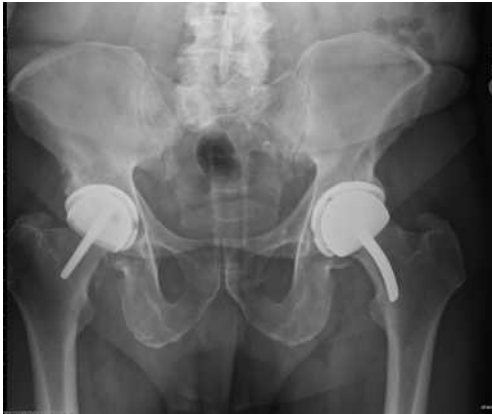

**Figure 2** This AP radiograph of a 45-year-old man shows a right total hip replacement and a left hip resurfacing. The same size acetabular shell size was used on each side.

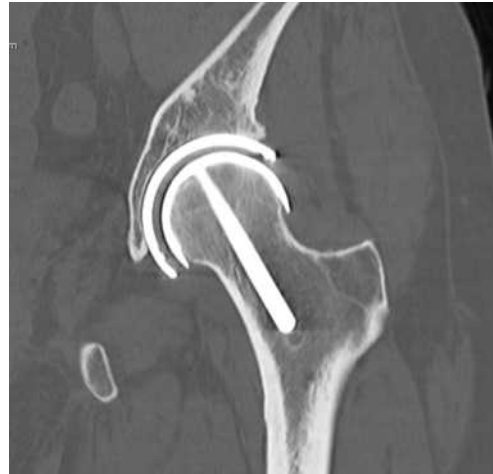intraoperatively. With under-reaming, critical acetabular bone is preserved. Because under-reaming is possible, most patients can be treated with the same size polyethylene acetabular component or just a 2-mm incremental increase compared to total hip replacement (26,32) (*Figure 2*).

Polyethylene wear with liner sizes up to 52.5 mm has been shown to be minimal both in clinical application and in wear simulator studies up to 30 million cycles (18). The wear experienced with hip resurfacing parallels the favorable wear seen with total hip replacement. However, edge loading from impingement is still a concern. The solution has been to use polyethylene fully supported by the acetabular shell (*Figure 1*). There are two acetabular polyethylene designs that have been used for resurfacing in which the polyethylene liner covers the edge of the metal backing leaving a vulnerability to impingement of the femoral neck against the polyethylene (26,27). The wear of highly cross-linked polyethylene has been studied using wear simulation, clinical retrievals, and by imaging using computed tomographic (CT) scans. All three methods suggest low wear equating to a lifetime of use.

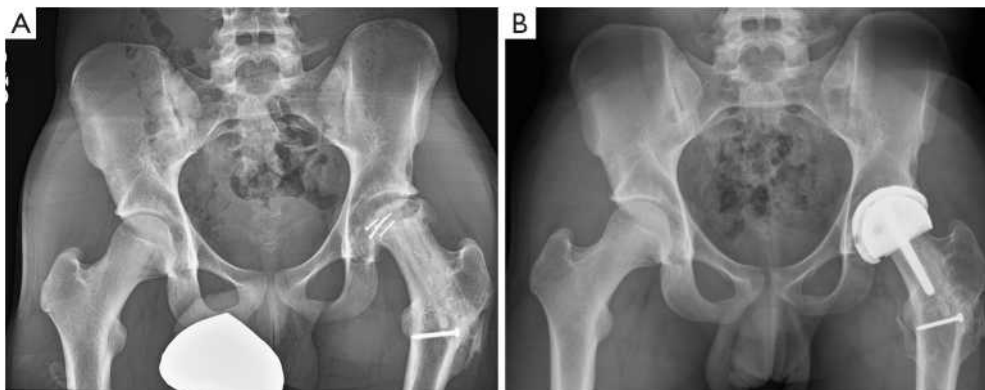
There have been few femoral component failures. Such failures are related to the fundamental health of the femoral head. Femoral components can be cemented yet, more recently, cementless fixation is performed and is an attractive option. The femoral component can be anatomic or flat topped (*Figure 3*). The author has had good success with a cementless anatomic femoral component. Ceramic-coated implants are attractive from a wear standpoint and they are appealing to patients who have concerns about reactions to implanted metals (33).



**Figure 3** This AP pelvic radiograph of a 72-year-old man is taken 20 years following hip resurfacing using bilateral highly cross-linked polyethylene acetabular components and a cementless Tara left femoral component with a curved stem and a right straight-stem prosthesis.



**Figure 5** This CT scan shows the bone retention and absence of acetabular wear 11 years following an entirely cementless hip resurfacing arthroplasty.



**Figure 4** This is a 15-year-old male who sustained a fracture dislocation of his left hip playing football. (A) This preoperative AP radiograph shows severe osteonecrosis and residuals of the prior operative repair and vascularized fibula graft; (B) the postoperative radiograph shows the resurfaced hip, using a two-piece acetabular component with a highly cross-linked polyethylene component and a resurfacing femur.

### Methods

Beginning in 1998, the author has implanted 2,154 highly cross-linked hip resurfacing prostheses in 1,931 patients. Thirty-two patients died and 35 were lost to follow-up. The same inclusion and exclusion criteria were used in this study of polyethylene hip resurfacing as have been used in other studies for metal-on-metal hip resurfacing. It was necessary to have geometry that would allow placement of the acetabular prosthesis with a least 5 mm of medial wall preservation and bone quality that was within the normal range (34,35). The femoral prostheses were cemented in 840

(39%) and uncemented in 1,314 (61%) patients (*Figure 3*). Follow-up examinations were performed at 8 weeks, 6 months, and annually, and outcomes were assessed using the Modified Harris Hip Score, WOMAC instrument, and UCLA Hip Score (36-38). Follow-up evaluation also included a digital anteroposterior (AP) view radiograph of the pelvis centered over the symphysis (*Figure 4*), an AP view of the hip centered over the femoral head, and a shoot-through lateral radiograph. High-resolution CT scans with metal-artifact reduction software were performed to look for polyethylene wear in 102 participants when they presented 6-11 years postoperatively (18) (*Figure 5*).

Table 1 Patient demographics and preoperative data

Characteristics	Women (n=873)	Men (n=984)	Non-binary (n=7)
Age (years), mean [range]	49 [19-67]	47 [15-68]	46 [29-61]
BMI (kg/m <sup>2</sup> ), mean [range]	25 [19-38]	29 [24-39]	27 [21-40]
Preoperative diagnoses (n=2,154)			
Osteoarthritis (n=862)	404	455	3
Prior trauma surgery (n=172)	64	108	0
Degeneration from dysplasia, Perthes disease, slipped epiphysis, other developmental disorders (n=1,077)	551	522	4
Avascular necrosis (n=43)	10	33	0

Table 2 Mean score and range of motion results

Measurement	Preoperative, mean [range]	Postoperative, mean [range]	P
HHS	51 [21-81]	97 [52-100]	<0.0001
WOMAC	52 [30-68]	4 [0-17]	<0.0001
UCLA	3 [2-7]	8 [6-10]	<0.0001
Flexion	84 [40-100]	119 [90-150]	<0.0001
Abduction	35 [30-55]	48 [30-70]	<0.0001

### *Wear simulator testing*

The author compared the wear of 30 highly cross-linked polyethylene resurfacing implants to conventional polyethylene using a wear simulator for 30 million cycles (18). The highly cross-linked implant had 93% less wear than the conventional polyethylene ( $P < 0.001$ ), which equates to more than 30 years of clinical use by highly active patients.

The materials and methods have been described in greater detail previously (26).

### **Results**

The follow-up period ranged from 5 to 21 years (median, 9.5 years). Patient demographics are shown in *Table 1*. The postoperative functional results all improved significantly (*Table 2*). Eighty percent of the patients achieved a postoperative UCLA score of 8 or greater. The average acetabular component inclination was 41° (range 30° to 53°) and the average anteversion was 15° (range, 0° to 25°). The average femoral anteversion was 13° (range, 0° to 20°). All femoral components were neutral or placed in a valgus orientation with respect to the native femur. Screw fixation was used in 9% of patients when the shell was >20%

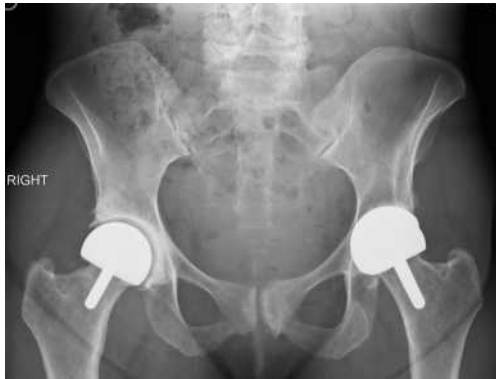uncovered.

### *Complications*

There were two dislocations that resolved nonoperatively. Eleven patients continued to report pain (five mild, four moderate, two significant). There were 21 deep infections; three were treated successfully by two-stage reimplantation and conversion to total hip replacement, 12 were treated with systemic antibiotics and implant retention with or without surgical debridement, two underwent a single-staged revision of the resurfacing implant (*Figure 6*), and four were treated with chronic suppression and implant retention.

### *Revisions*

Twenty-four patients (1%) underwent successful revision of their femoral component to a stem-supported implant from 3 to 20 years following the initial surgery. The causes of failure were femoral neck fracture (12), femoral loosening or subsidence (9), and infection (3). Two patients had a revision of their femoral resurfacing component to



**Figure 6** This AP radiograph was taken 15 years following bilateral hip resurfacing arthroplasty in a 61-year-old woman. On the left is a metal-on-metal prosthesis and on the right, there is a cemented (with antibiotics) all polyethylene acetabular component and cemented femoral component placed as a revision for an infected right hip resurfacing prosthesis.

another femoral resurfacing component. In all revisions, the metal-backed acetabular component was retained and the acetabular liner was exchanged to allow use of a smaller or the same highly cross-linked polyethylene. There were five acetabular revisions for loosening. A new shell with screw fixation resulted in a secure component and successful outcome. Using revision for any reason as the endpoint, the Kaplan-Meier survival estimate of mean survivorship was 97.5% (95% CI, 95-98.9%) at 10 years (*Figure 3*). There were no bearing-surface failures or pending revisions.

### **Retrievals**

There were 32 polyethylene implants retrieved during revision surgery or postmortem. The implants were retrieved from 3 to 20 years after placement. Examination found minimal wear ranging from 0.003 to 0.07 mm/year and no visible evidence of damage to the polyethylene.

### **Bone retention**

*Figure 5* shows the bone retention and absence of acetabular wear 11 years following an entirely cementless hip resurfacing arthroplasty. The results of bone retention evaluation have been reported previously (32). Briefly, the mean acetabular wall was 10 mm thick postoperatively vs. 15 mm preoperatively, the head: neck ratio was 1.36 postoperatively compared to 1.42 preoperatively. The leg length increased a mean of 4 mm postoperatively. The acetabular component was a mean of 3.9 mm to Kohler's line and there were no instances of compromise to the femoral neck or medial

wall.

### **Deformation testing**

Acetabular under-reaming is a bone preservation and fixation strategy in hip resurfacing. All prior reports of acetabular component deformation have been cadaveric studies (31). I assessed the deformation of the thin shells and very thin highly cross-linked polyethylene in 32 acetabular components retrieved postmortem or during revision after a mean of 9 years of patient use. They had been placed with 3 mm of under-reaming. Deformation of the shells and liners was measured during insertion, 30 minutes after implantation, after reducing the hip and testing range of motion, and at retrieval. The acetabular shells deformed a mean of 0.58 mm on insertion. At retrieval the residual deformation was 0.23 mm. The initial liner deformation was 0.29 mm decreasing to 0.15 mm on retrieval. The calculated insertional force was 367 Nm. There were no acetabular fractures, and no shell or liner failures. The thin resurfacing acetabular shells and liners deform when placed with 3 mm of under-reaming. The deformation becomes less with loading, bone relaxation, and clinical use. There were no adverse clinical consequences from under-reaming and all implants performed well. The bone preservation provided by under-reaming is beneficial during hip resurfacing surgery.

### **Efficiency of treatment**

The author recorded the time of answering questions for patients presenting for hip resurfacing and patients presenting for total hip replacement. The interview time spent with resurfacing patients had an overall mean of 49 minutes compared with 24 minutes for total hip replacement. Themes were identified using qualitative interviews. For resurfacing patients their hip function was integral to their sense of well-being and self-efficacy. Resurfacing patients self-identified as having different needs and higher demands than other patients. Resurfacing patients used medical literature and the internet as first sources of information and physician information as their second source. Care coordinators found additional instruction and trust building was necessary with hip resurfacing patients. The operative time was also longer, with mean of 88 minutes compared with 64 minutes for total hip replacement.

### **Discussion**

Hip resurfacing using highly cross-linked polyethylene is a successful procedure. It is a conceptually attractive solution to hip arthritis for young and active patients. There are four practical considerations that are limiting for hip resurfacing: (I) hip resurfacing is a difficult

technical procedure that invites errors. Because of the more difficult exposure, demanding planning and execution, surgeons are more attracted to the more efficient total hip replacement alternative; (II) resurfacing implants are typically more expensive and less available; (III) the procedural coding and payment systems typically do not recognize the additional challenges resurfacing presents, with payment the same as total hip replacement; (IV) hip resurfacing patients are younger, more engaged, and often ask more questions and have higher expectations than older patients and consume more staff and surgeon time. By comparison, total hip replacement represents a more efficient procedure. Also, the weight of opinion and authority recommends hip replacement rather than hip resurfacing. The clinical performance and preference of resurfacing patients, however, leads to a better overall outcome. Because of the ceiling effect of outcome tools, accurately measuring and demonstrating additional value for hip resurfacing has been a challenge.

There are young patients whose needs and expectations will not be met by total hip replacement. The retention of femoral bone, smaller volume of implanted material, and ability to offer the procedure when the medullary canal is blocked are all procedural advantages of hip resurfacing. The functional advantages for resurfacing patients are enhanced stability, ability for sports and other physically demanding endeavors, and a lower incidence of mortality at 10 years compared to hip replacement (39-43). In addition, infection, when it occurs, is more easily managed without intrusion into the femoral canal.

The successful reports about hip resurfacing may seem systematically biased. It is possible to control for bias by: (I) using independent, blinded third-party examiners; (II) using well-designed qualitative questions with sufficient followup; (III) recognizing that randomized trials comparing hip resurfacing arthroplasty to total hip replacement in different patients have not shown any influence of patient preoperative preference on either their outcome or postoperative preference (44), and (IV) recognizing that patients do not always correctly recall which procedure they received and, therefore, are not always able to form a bias. The expectations patients have for resurfacing are higher for both function and survivorship than for total hip replacement. Comparison studies have shown a preference for hip resurfacing. Patients with a resurfaced hip on one side and a hip replacement on the other have consistently expressed a strong preference for hip resurfacing arthroplasty (45,46).

The 20-year results of using conventional polyethylene for hip resurfacing with the Indiana Conservative Hip (DePuy, Warsaw, IN), THARIES, TARA and Wagner (Zimmer Biomet, Warsaw, IN) were poor (1,4,5,47). Improved techniques and instrumentation and the use of highly cross-linked polyethylene have resulted in much better

outcomes and survivorship. The issues with metal-on-metal and the potential issues of squeaking, fracture, and stress shielding with ceramic-on-ceramic can be avoided. Polyethylene is familiar and well-studied. Improvements in intraoperative technique have included intraoperative imaging, a cannulated system for placing the femoral guide pin, cementless fixation, more effective impactors for the acetabular shell and liner, and possibly computer-assisted surgery. A deeper understanding and better management of acetabular shell deformation have resulted in better fixation and better bone conservation.

Hip resurfacing is successful in conserving acetabular bone compared to total hip replacement (26,29,47,48). Preserving femoral bone is not only advantageous in case of a revision but also functionally. Revision surgery in the uncommon and unwelcome event of failure in this study was successful in producing an outcome equivalent to primary hip replacement.

Earlier concerns with conventional polyethylene relative to wear, thickness, osteolysis, and deformation have been solved with cross-linked polyethylene (26,32,49). The currently available implants are successful but even thinner one-piece implants may be possible. However, one-piece implants require the use of an effective suction, negative pressure or pegged acetabular inserter, which is complicated, and preclude supplemental dome screw fixation and independent liner exchanges. Also, managing the deformation of one-piece components is more challenging. The implants described in this study have been successful enough to continue offering polyethylene hip resurfacing with confidence. These are not custom-made components (27).

There are limitations to this work. All the procedures were performed by a single very experienced surgeon. Thus, it is possible that the results would not be reproducible in other centers. A multicenter study would have been preferred and additional centers are now being added to continue this research. Similar but not identical implants were used. Smaller studies using a consistent implant and technique have been published (26,32). The follow-up in this study was midterm but some results have extended to 21 years.

Townley, Amstutz, and Buechel came close, but did not reach success with conventional polyethylene for hip resurfacing (1,29,50). They each looked at highly cross-linked polyethylene and the present work extends and adds further evidence that highly cross-linked polyethylene is the next step in the evolution of hip resurfacing (15,30,51). Improvements that have led to success using polyethylene for hip resurfacing are: (I) improved operative technique, (II) improved instrumentation, (III) improved management and understanding of acetabular shell and liner deformation, and (IV) additional and longer implant testing and clinical follow-up. Hip resurfacing arthroplasty using highly cross-linked polyethylene is a reliable and durable procedure that meets even the highest demands of younger active patients.

## Acknowledgments

None.

## Footnote

*Conflicts of Interest:* The author has no conflicts of interest to declare.

*Ethical Statement:* The author is accountable for all aspects of the work in ensuring that questions related to the accuracy or integrity of any part of the work are appropriately investigated and resolved. The study was approved by the Institutional Review Board approval (# 5190S-11) and the investigation was conducted in conformity with ethical principles of research and that informed consent was obtained.

## References

- Pritchett JW. Success rates of the TARA hip. *Am J Orthop* 1998;27:658.
- Pritchett JW. Curved-stem hip resurfacing: minimum 20-year followup. *Clin Orthop Relat Res* 2008;466:1177-85.
- Freeman MA. Total surface replacement hip arthroplasty. *Clin Orthop Relat Res* 1978;(134):2-4.
- Yue EJ, Cabanela ME, Duffy GP, et al. Hip resurfacing arthroplasty: risk factors for failure over 25 years. *Clin Orthop Relat Res* 2009;467:992-9.
- Costi K, Howie DW, Campbell DG, et al. Long-term survival and reason for revision of Wagner resurfacing hip arthroplasty. *J Arthroplasty* 2010;25:522-8.
- Malviya A, Lobaz S, Holland J. Mechanism of failure eleven years following a Buechel Pappas hip resurfacing. *Acta Orthop Belg* 2007;73:791-4.
- de Steiger RN, Miller LN, Prosser GH, et al. Poor outcome of revised resurfacing hip arthroplasty. *Acta Orthop* 2010;81:72-6.
- Dunbar MJ, Prasad V, Weerts B, et al. Metal-on-metal hip surface replacement: the routine use is not justified. *Bone Joint J* 2014;96-B:17-21.
- Pritchett JW. Letter to the Editor: Poor survivorship and frequent complications at a median of 10 years after metal-on-metal hip resurfacing revision. *Clin Orthop Relat Res* 2017;475:1747-8.
- Pritchett JW. One-component revision of failed hip resurfacing from adverse reaction to metal wear debris. *J Arthroplasty* 2014;29:219-24.
- de Waal Malefijt MC, Huiskes R. A clinical, radiological and biomechanical study of the TARA hip prosthesis. *Arch Orthop Trauma Surg* 1993;112:220-5.
- Hellman MD, Ford MC, Barrack RL. Is there evidence to support an indication for surface replacement arthroplasty?: a systematic review. *Bone Joint J* 2019;101-B:32-40.
- Kurtz SM, Gawel HA, Patel JD. History and systematic review of wear and osteolysis outcomes for first-generation highly crosslinked polyethylene. *Clin Orthop Relat Res* 2011;469:2262-77.
- Mall NA, Nunley RM, Zhu JJ, et al. The incidence of acetabular osteolysis in young patients with conventional versus highly crosslinked polyethylene. *Clin Orthop Relat Res* 2011;469:372-81.
- Pritchett JW. Conservative total articular replacement arthroplasty: minimum 20-year follow-up. In: McMinn DJW, editor. *Modern hip resurfacing*. New York: Springer, 2009:408-14.
- Blakeney WG, Beaulieu Y, Puliero B, et al. Excellent results of large-diameter ceramic-on-ceramic bearings in total hip arthroplasty: Is Squeaking Related to Head Size. *Bone Joint J* 2018;100-B:1434-41.

Annals of Joint. All rights reserved.

year followup. *Clin Orthop Relat Res* 2008;466:1177-85.

3. Freeman MA. Total surface replacement hip arthroplasty. *Clin*



17. Yoon BH, Park IK. Atraumatic fracture of the BIOLOX delta ceramic liner in well-fixed total hip implants. *Orthopedics* 2018;41:e880-3.
18. Pritchett J. Very large diameter polymer acetabular liners show promising wear simulator results. *J Long Term Eff Med Implants* 2016;26:311-9.
19. Cobb JP, Clarke SJ, Jeffers J, et al. Anatomic ceramic hip resurfacing arthroplasty: first in human trials. *Orthop Proc* 2018;100B:29.
20. Pritchett J. Heat generated by hip resurfacing prostheses: in vivo pilot study. *J Long Term Eff Med Implants* 2011;21:55-62.
21. Bartel DL, Bicknell VL, Wright TM. The effect of conformity, thickness, and material on stresses in ultra- high molecular weight components for total joint replacement. *J Bone Joint Surg Am* 1986;68:1041-51.
22. Shen FW, Lu Z, McKellop HA. Wear versus thickness and other features of 5-Mrad crosslinked UHMWPE acetabular liners. *Clin Orthop Relat Res* 2011;469:395-404.
23. Lachiewicz PF, Heckman DS, Soileau ES, et al. Femoral head size and wear of highly cross-linked polyethylene at 5 to 8 years. *Clin Orthop Relat Res* 2009;467:3290-6.
24. Kelly NH, Rajadhyaksha AD, Wright TM, et al. High stress conditions do not increase wear of thin highly crosslinked UHMWPE. *Clin Orthop Relat Res* 2010;468:418-23.
25. Martell JM, Verner JJ, Incavo SJ. Clinical performance of a highly cross-linked polyethylene at two years in total hip arthroplasty: a randomized prospective trial. *J Arthroplasty* 2003;18:55-9.
26. Pritchett JW. Hip resurfacing using highly cross-linked polyethylene: prospective study results at 8.5 years. *J Arthroplasty* 2016;31:2203-8.
27. Treacy RBC, Holland JP, Daniel J, et al. Preliminary report of clinical experience with metal-on-highly- crosslinked- polyethylene hip resurfacing. *Bone Joint Res* 2019;8:443-50.
28. Le Duff MJ, Wang CT, Wisk LE, et al. Benefits of thin- shelled acetabular components for metal-on-metal hip resurfacing arthroplasty. *J Orthop Res* 2010;28:1665-70.
29. Buechel FF. Hip resurfacing revisited. *Orthopedics* 1996;19:753-6.
30. Buechel FF Sr, Pappas MJ. A metal/ultrahigh-molecular- weight polyethylene cementless surface replacement. *Semin Arthroplasty*;2011;22:66-74.
31. Markel D, Day J, Siskey R, et al. Deformation of metal- backed acetabular components and the impact of liner thickness in a cadaveric model. *Int Orthop* 2011;35:1131-7.
32. Pritchett JW. Hip resurfacing with a highly cross-linked polyethylene acetabular liner and a titanium nitride-coated femoral component. *Hip Int* 2018;28:422-428.
33. Pappas MJ, Makris G, Buechel FF. Titanium nitride ceramic film against polyethylene. A 48 million cycle wear test. *Clin Orthop Relat Res* 1995;(317):64-70.
34. Beaulé PE, Antoniadou J. Patient selection and surgical technique for surface arthroplasty of the hip. *Orthop Clin North Am* 2005;36:177-85.
35. Schmalzried TP, Silva M, de la Rosa MA, et al. Optimizing patient selection and outcomes with total hip resurfacing. *Clin Orthop Relat Res* 2005;441:200-4.
36. Amstutz HC, Le Duff MJ, Campbell PA, et al. Clinical and radiographic results of metal-on-metal hip resurfacing with a minimum ten-year follow-up. *J Bone Joint Surg Am* 2010;92:2663-71.
37. Harris WH. Traumatic arthritis of the hip after dislocation and acetabular fractures: treatment by mold arthroplasty. An end-result study using a new method of result evaluation. *J Bone Joint Surg Am* 1969;51:737-55.
38. Ware JE, Kosinski M, Keller SD. How to score the SF- 12 physical and mental health summary scales. 3rd ed. Lincoln, RI: Quality Metric Incorporated, 1998.
39. Haddad FS, Konan S, Tahmassebi J. A prospective comparative study of cementless total hip arthroplasty and hip resurfacing in patients under the age of 55 years: a ten- year follow-up. *Bone Joint J* 2015;97-B:617-22.
40. Barrack RL, Ruh EL, Berend ME, et al. Do young, active patients perceive advantages after surface replacement compared to cementless total hip arthroplasty? *Clin Orthop Relat Res* 2013;471:3803-13.
41. Costa ML, Achten J, Parsons NR, et al. Total hip arthroplasty versus resurfacing arthroplasty in the treatment of patients with arthritis of the hip joint: single centre, parallel group, assessor blinded, randomised controlled trial. *BMJ* 2012;344:e2147.
42. McMinn DJ, Snell KI, Daniel J, et al. Mortality and implant revision rates of hip arthroplasty in patients with osteoarthritis: registry based cohort study. *BMJ* 2012;344:e3319.
43. Kendal AR, Prieto-Alhambra D, Arden NK, et al. Mortality rates at 10 years after metal-on-metal hip resurfacing compared with total hip replacement in England: retrospective cohort analysis of hospital episode statistics. *BMJ* 2013;347:f6549.
44. Bisseling P, Smolders JM, Hol A, et al. No clear influence of preference bias on satisfaction and early functional outcome in resurfacing hip arthroplasty. *Acta Orthop* 2011;82:161-5.
45. Fowble VA, dela Rosa MA, Schmalzried TP. A comparison of total hip resurfacing and total hip arthroplasty-patients and outcomes. *Bull NYU Hosp Jt Dis* 2009;67:108-12.
46. Ortiz-Declet VR, Iacobelli DA, Yuen LC, et al. Birmingham hip resurfacing vs total hip arthroplasty: a

- matched-pair comparison of clinical outcomes. *J Arthroplasty* 2017;32:3647-51.
47. Loughhead JM, Starks I, Chesney D, et al. Removal of acetabular bone in resurfacing arthroplasty of the hip: a comparison with hybrid total hip arthroplasty. *J Bone Joint Surg Br* 2006;88:31-4.
48. Vendittoli PA, Lavigne M, Girard J, et al. A randomised study comparing resection of acetabular bone at resurfacing and total hip replacement. *J Bone Joint Surg Br* 2006;88:997-1002.
49. Pritchett JW. Reply to Dr. Ranawat's letter to the editor. *Ann Joint* 2016;1:25-26.
50. Tan TL, Ebramzadeh E, Campbell PA, et al. Longterm outcome of a metal-on-polyethylene cementless hip resurfacing. *J Arthroplasty* 2014;29:802-7.
51. Amstutz HC, Takamura KM, Ebramzadeh E, et al. Highly cross-linked polyethylene in hip resurfacing arthroplasty: long-term follow-up. *Hip Int* 2015;25:39-43.

doi: 10.21037/aoj.2019.12.09

**Cite this article as:** Pritchett JW. Polyethylene for hip resurfacing—worth a second look. *Ann Joint* 2020;5:10.