

SURGERY FOR NERVE INJURY FOLLOWING HIP REPLACEMENT

James W. Pritchett MD, 901 Boren Ave, Seattle, WA 98104. bonerecon@aol.com

Background: During hip replacement, the nerves in the operative field can be injured accidentally. Every surgeon who performs hip replacements regularly will be faced, at some point, with a serious nerve injury. There are often delays in diagnosis and these injuries are underreported. Most literature has focused on understanding risk factors and preventive measures. There are additional surgical procedures that can help restore the lost function or reduce pain. These procedures include nerve repair, neurolysis, limb shortening, sympathectomy, and tendon transfer.

Spinal decompression can be helpful if there is a double-crush syndrome (Fig. 1).

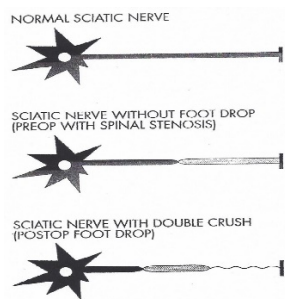


Fig. 1

Methods: This review includes patients treated for 34 years after the author was introduced to allograft nerve surgery by Dr. Leonard Marmor (Nicolas Andry Award 1963). One hundred sixty-two patients from 94 initial surgeons presented with nerve injuries from hip replacement surgery. Of these, 68% were offered additional surgery. There were 91 procedures performed on the injured limb for 80 patients. In addition, there were 30 spinal decompressions and 3 peroneal nerve decompressions at the fibular neck. There were 101 sciatic, 34 femoral, 14 obturator, and 13 combined injuries. All patients had injuries with major function loss and that was not expected to or had not recovered after 6 months. Also, 100 patients (62%) had lost confidence in their hip replacement surgeon due to the delayed or missed diagnosis or failure to offer additional procedures to treat the nerve injury. All 80 patients treated had motor loss of at least 2 grades or pain ≥ 5 . A meaningful recovery was defined as an increase of 1 or more level in strength or a reduction of 2 or more points on the visual analog pain scale.

Results: Procedures performed and outcomes are shown in the Table.

Procedure Type (n)	Treatment Performed (n)	Meaningful Recovery (n)
Nerve repair/graft (15)	Femoral nerve allograft (2)	1
	Femoral nerve repair (2)	1
	Sciatic nerve repair (6)	1
	Sciatic nerve allograft (2)	1
	Obturator nerve resection (1)	0
	Obturator nerve buried in muscle (2)	2
	Neurolysis/decompression (28)	Neurolysis for incarcerations in the capsular repair (7)
	or adjunctive fixation:	
	screws (3)	3
	wires (4)	2
	cages (2)	2
	cement (2)	1
	additional nerves embedded in scar (10)	9
Limb Shortening (21)	Acetabular revisions (4)	3
	Femoral head exchanges (14)	10
	Femoral stem revisions (3)	2
Sympathectomy (7)	Sympathectomy (7)	6
Tendon Transfer (20)	Posterior tibial tendon for foot dorsiflexion (17)	16
	Hamstring for knee extension (3)	2
Spinal decompression (30)	Lumbar (29)	24
	Cervical (1)	1
Peroneal decompression (3)	Peroneal nerve decompression at fibular neck (3)	2

Eighty-two percent of patients achieved a dual benefit of improved function and less pain from the neurolysis, tendon transfer, shortening, or sympathectomy. Overall, 40% of patients made a meaningful recovery from repair, grafting or burying a damaged nerve (Fig. 2).

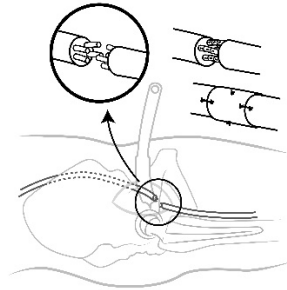


Fig. 2

Three nerve lacerations or resections were discovered at the time of surgery and the remaining 12 were discovered 2 - 720 days later; no patient over 55 years old made a meaningful recovery from nerve repair or graft surgery (Fig. 2). There were 6 (5.3%) surgical complications from the additional reconstructive procedures including worsening pain in 2, infection in 2, and deformity from tendon transfer in 2.

Anatomical variations in nerve anatomy were present in 19 (24%) of nerve injury patients. Scar from a prior femoral artery catheterization procedure was present in 10 of the 34 femoral nerve injuries. Ninety-five percent of femoral artery catheterizations are performed on the right side. Forty-six percent of patients sought legal advice and 29% filed a claim. Overall, 16% of patients received financial compensation and all had a delayed diagnosis. Among 1409 general public participants responding to a survey, 17% indicated a nerve injury represents professional negligence.

Discussion: Not all nerve injuries can be avoided. Most serious injuries will not recover. It is common for patients to lose confidence if there is a delay in diagnosis, poor communication, or limited discussion of treatment options. The 38% of patients who remained confident in their surgeon stated they had received diligent care, prompt diagnosis, and complete information. Surgical procedures can be offered to patients with sustained functional loss from nerve injury following hip replacement. Nerve decompression and limb shortening are not complex and usually result in improvement. Tendon transfers and spinal decompression are helpful to most patients. Nerve repair and grafting are helpful in younger patients when performed early. Neurolysis and sympathectomy can reduce dysesthetic pain.

A missed or delayed diagnosis of nerve injury can occur because the surgeon's attention is focused elsewhere, either during hip replacement or postoperatively. Under-recognition and under-reporting of nerve injury is common. Large data surveys often find nerve injuries are not identified until after hospital discharge. Missing the nerve injury

reduces the chance of achieving a successful outcome and makes the relationship with the patient more difficult.

Most consent forms specifically mention nerve injury as a risk. Discussing nerve injury during shared decision can support confidence.

Conclusions: A thorough postoperative examination, appropriate imaging and testing, and a willingness to consider additional reconstructive measures are the keys to treatment. Prior femoral artery catheterization can contribute to or complicate femoral nerve injury with hip replacement. If the nerve was not identified in the index procedure, there should be a low threshold for nerve exploration. Allowances can be made for the injury as part of the surgical risk but little allowance can be made for delay in diagnosing nerve injury and offering prompt assessment, supportive counseling, and comprehensive treatment.