



Long-term results and patient satisfaction after shoulder resurfacing

James W. Pritchett, MD*

Orthopedics International, Seattle, WA, USA

Background: Shoulder resurfacing has regained popularity in recent years. This report presents the long-term (>20 years) results of this procedure with regard to patient satisfaction and implant survival.

Materials and methods: We followed up 61 patients who underwent shoulder resurfacing procedures (74 shoulders) for a minimum of 20 years or until death (7 additional patients were lost to follow-up). The mean patient age at the time of surgery was 58 years. There were 41 total resurfacing procedures and 33 hemi-resurfacing procedures. The humeral component consisted of a cup with a short central peg that was placed either with or without cement. The glenoid was resurfaced with a cemented polyethylene or polyurethane component.

Results: Patient satisfaction was 95%, and the survivorship of the humeral prostheses was 96%. There were no periprosthetic fractures, dislocations, or infections. Two humeral components were revised to stemmed prostheses (one for loosening and one for unexplained pain), and one was revised from a cementless to a cemented resurfacing prosthesis. Twelve cemented polyethylene glenoid prostheses had radiolucencies, but only three produced symptoms requiring revision surgery; three polyurethane glenoid prostheses showed severe wear radiographically, but none was loose or required revision surgery. There were 7 revision procedures, 6 with good results.

Conclusions: Shoulder resurfacing is a successful procedure for the majority of patients, with high rates of patient satisfaction, long-term survivorship of the humeral prosthesis, and few complications.

Level of evidence: Level IV, Case Series, Treatment Study.

© 2011 Journal of Shoulder and Elbow Surgery Board of Trustees.

Keywords: Shoulder; shoulder resurfacing; humeral implant

The first total shoulder resurfacing procedure is believed to have been performed by Dr Charles O. Townley in 1958 using a metal humeral component and a polyurethane glenoid. Subsequent shoulder resurfacing procedures were performed by use of small hip resurfacing prostheses.^{11,25} Zippel²⁹ in 1975 was the first investigator to publish a report describing the use of a metallic surface replacement of the humeral head. However, with the advent of stem-

supported shoulder prostheses, shoulder resurfacing was largely abandoned, with the exception of a few surgeons.^{17,18} Recently, cementless hemi-resurfacing and total shoulder resurfacing prostheses have again become popular, and results at midterm follow-up have been favorable.^{5,9,15,16}

Shoulder resurfacing may offer several procedural benefits to both the surgeon and patient. The humeral head is retained, theoretically facilitating correct version, offset, and inclination of the prosthesis during surgery.^{2,5} Stem-supported total should arthroplasty is a reliable treatment for degenerative conditions of the glenohumeral joint, and reports suggest pain relief and implant survivorship of 84%

*Reprint requests: James W. Pritchett, MD, Orthopedics International, 901 Boren Ave, Ste 800, Seattle, WA 90104.
E-mail address: bonerecon@aol.com




Figure 1 Total Articular Replacement Arthroplasty components. The cobalt chromium humeral component has a central stem. The glenoid is made from polyethylene and has a central keel.

to 96% at 12 years.^{3,24,26,28} However, for the humerus, shoulder resurfacing may be easier than preparing the patient for and inserting a stemmed supported prosthesis,^{5,15} although glenoid exposure can be difficult when the humeral head is not resected. In addition, a shoulder resurfacing prosthesis can be used on a humerus with in situ implanted fixation or a deformity that would preclude the placement of a humeral stem.

This study was conducted to determine the long-term (>20 years) outcome of shoulder resurfacing by assessing the following primary and secondary outcomes: (1) patient satisfaction and (2) the survivorship of the implant.

Materials and methods

Institutional review board approval was not required at the time the patients were enrolled in the study. None of the patients had undergone prior implant arthroplasty, although 18 patients had undergone prior surgery to treat a fracture, dislocation, impingement syndrome, or rotator cuff tear. All patients had been treated extensively but unsuccessfully with nonoperative methods. All patients were dissatisfied with their shoulder function and were unwilling to continue to endure their symptoms of severe pain and limitations in function. All patients opted for surgical treatment even when advised by the surgeons that there was no certainty of a successful outcome.

The initial study population consisted of 68 adult patients (84 shoulders) who underwent shoulder resurfacing surgery with the Total Articular Replacement Arthroplasty prosthesis (DePuy Orthopaedics [Warsaw, IN] and Howmedica [Rutherford, NJ]) between 1958 and 1990 (Fig. 1). The final study population described in this report consisted of 61 adult patients (74 shoulders), because 7 patients were lost to follow-up and were, thus, not included. There were 32 women and 29 men with a mean age of 58 years (range, 32-71 years). Preoperative diagnoses included osteoarthritis (37 shoulders [50%]), post-traumatic arthritis (20 shoulders [27%]), inflammatory arthritis (12 shoulders [16%]), and osteonecrosis (5 shoulders [7%]). The indication for surgery was severe pain associated with limitations in function for all

patients. Exclusion criteria were prior infection of the shoulder, severe deformity of the humeral head, and neurologic injuries. Rotator cuff insufficiency was accepted in the absence of superior humeral head escape. Because patient data included in this report began to be collected more than 50 years ago, it is not possible to report with accuracy the number of patients who underwent a shoulder arthroplasty other than resurfacing; however, a rough estimate would be 3 to 4 times as many than underwent resurfacing. Patients who met the inclusion criteria were offered the option of undergoing the resurfacing procedure.

Patients were followed up prospectively and asked to return at 1 year, 2 years, and 5 years and then every 5 years thereafter. To determine patient satisfaction, at the follow-up examinations, patients were asked about their activity and whether their resurfaced shoulder limited any of their activities. Any limitations were specific to that particular patient's life goals. Data reported in this study consisted of the patients' self-reported satisfaction at the 20-year follow-up visit. All deceased patients had a follow-up visit within 4 years of their death (range, 4-46 months); data were derived from their self-reported satisfaction (ie, their verbal responses of "very satisfied," "satisfied," "somewhat satisfied," "somewhat disappointed," or "very disappointed" that were noted on their medical records during their final visit). Patients were asked whether any additional surgery had been performed after their resurfacing procedure. Implant survival was defined as implants for which revision was not performed or recommended. All patients were followed up for a minimum of 20 years or until death.

Postoperative radiographs were assessed by the author retrospectively for the presence or absence of radiolucent lines and their width in relation to time after resurfacing. Definite loosening was defined as a change in the position of the component, and possible loosening was defined as an unchanged position but progressive radiolucent lines involving all parts of a component. Because radiographs were not standardized (ie, different technicians and different and vastly improved techniques and equipment over many years), no specific radiographic measurements of the humeral component were made. We used the grading system described by Franklin et al⁷ for the glenoid. To allow comparison to other studies, we also used the Constant score. In addition, none of the currently available functional scoring systems were used,

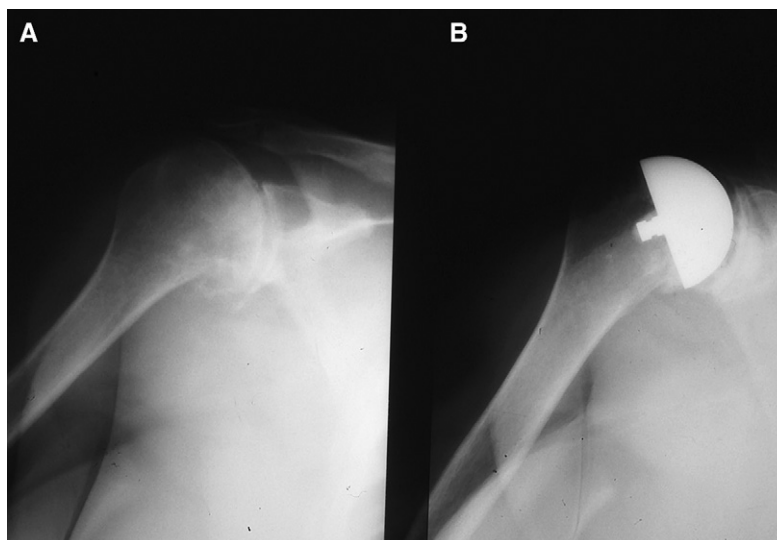


Figure 2 Anteroposterior shoulder radiographs. **A**, Preoperative image with advanced glenohumeral arthritis. **B**, Postoperative image taken after insertion of total resurfacing prosthesis.

because the first such system was developed in 1987 and nearly all patients in this report had been treated by that time.⁴ Consequently, subjective postoperative results as rated by the patients are presented.

Operative procedure

Each operation was performed by 1 of 2 surgeons (J.W.P. or Charles O. Townley, MD). A deltopectoral approach was used for all procedures. The subscapularis tendon was incised vertically 1 cm medial to the lesser tuberosity, isolated from the joint capsule, and retracted medially. The shoulder was dislocated anteriorly by external rotation. The labrum was debrided as necessary, and any contractures were released. The humeral head was measured and prepared with a milling device to accept the humeral cup. The humeral prosthesis with the best head coverage was placed in anatomic version, and an anatomic repair of the subscapularis was performed. We placed 3 of the earliest humeral components without cement using a bolt through the lateral humeral cortex, 30 humeral components were placed without a bolt and without cement, 37 humeral components were cemented with polymethylmethacrylate (Simplex; Howmedica), and 4 humeral components were cemented with polyurethane cement (Ostamer; William S. Merrell, Cincinnati, OH). The polyurethane polymer was prepared by mixing the pre-polymer with resin and a catalyst at the time of surgery and molding it in situ or on the back table to the humeral prosthesis. The humeral prostheses were all made of cobalt chromium (DePuy Orthopaedics and Howmedica) (Fig. 2).

There were 41 glenoids implanted. The glenoid components were always cemented in place. Polyurethane cement was used for the polyurethane glenoid components, but the polyethylene glenoid prostheses were cemented with polymethylmethacrylate. The polyethylene glenoid prostheses became available in 1971 and had a central keel (Howmedica and DePuy Orthopaedics). Polyurethane glenoid prostheses were used from 1958 until 1962, when the vendor stopped selling the product. No reaming or preparation of the glenoid is done when a hemiarthroplasty is performed.

Postoperative protocol

Patients used a standard sling on the operated extremity for 6 weeks postoperatively. Home exercises were started on the first postoperative day and consisted of passive circumduction and pendulums, as well as active range-of-motion exercises such as saws (ie, back-and-forth motion of the arm in the coronal plane with a flexed elbow). External rotation was allowed to within 30° of that obtained intraoperatively after subscapularis repair. Patients participated in either a formal physical therapy program or a therapist-directed home program for an additional 6 weeks. No limitations were placed on patients' activities after 3 months postoperatively.

Results

By the time of final follow-up, 42 patients (69%) had died at a mean age of 81 years (range, 59-92 years). The mean follow-up was 28 years (range, 20-41 years) (Table I). There were 41 total resurfacing procedures and 33 hemiarthroplasties. Total arthroplasties were performed when substantial glenoid erosion was present. Excluding the patients who underwent revision surgery, 95% of the patients were satisfied with their shoulder resurfacing procedure; Table II shows the patient-reported results. Of the patients assessed for postsurgical activity, 39% participated in strenuous athletics or work and only 2 were dissatisfied with their function; overall, 92% of patients were not limited in their activities. Table III shows the shoulder motion after resurfacing, and Table IV shows the preoperative and postoperative Constant scores. There were no differences in satisfaction or function according to whether the patient had a hemi-resurfacing or total resurfacing procedure.

Table I Survivorship of 61 patients

Years since surgery	No. (%)	Mean age at death or final follow-up y (range)
Deceased	42 (69%)	81 (59-92)
20-30	23	
30-40	17	
>40	2	
Alive	19 (31%)	75 (54-94)
20-30	11	
30-40	6	
>40	2	

Table II Patient-reported postoperative results (61 patients [74 shoulders])

Self-reported outcomes	No. of patients/shoulders (% of patients)
Pain	
None	52/63 (85%)
Slight	7/9 (11%)
Moderate	1/1 (2%)
Severe	1/1 (2%)
Function	
Highly active (strenuous sports or job)	24/29 (39%)
Active (no limitations)	31/38 (51%)
Moderately active	4/5 (7%)
Inactive	2/2 (3%)
Satisfaction	
Very satisfied	31/36 (50%)
Satisfied	22/27 (36%)
Somewhat satisfied	4/7 (9%)
Somewhat/very disappointed	4/4 (5%)

There were no infections, subluxations, or periprosthetic fractures. There were 2 temporary nerve palsies, 1 involving the entire brachial plexus and 1 involving the axillary nerve only. The radiographic follow-up period averaged 24 years (range, 20-36 years). Of 41 glenoid components implanted, 3 were revised, thus leaving 38 glenoid prostheses available for final review. Radiographic review showed grade 0 in 2, grade 1 in 7, grade 2 in 8, grade 3 in 8, grade 4 in 12, and grade 5 in 1; the 3 that were revised were grade 5.⁷ As mentioned previously, the procedures in this report began more than 50 years ago, and early radiographic quality was far poorer than more recent radiographic data. Of the polyethylene glenoid prostheses, 12 were loose (definitely, $n = 4$; possibly, $n = 8$) but only 4 were symptomatic. Three of four polyurethane components showed wear through but none loosened or required revision, and all four of these patients continued to report a satisfactory outcome. After the polyurethane wore away, these shoulders seemed to function as hemiarthroplasties.

Table III Mean shoulder motion after resurfacing (increase)

	Normal shoulder ¹⁴	Hemiarthroplasty	Total resurfacing
No. of shoulders	10	33	41
Abduction (°)	178	105 (47)	109 (46)
Flexion (°)	170	112 (41)	119 (45)
External rotation (°)	64	43 (26)	44 (27)
Internal rotation	L2 + 2	L4 + 2	L4 + 2

There were 7 revision surgeries, 6 with ultimate good outcomes. One of the earliest cementless hemi-resurfacing components was revised to a cemented total resurfacing prosthesis because of loosening of the humeral component and glenoid wear. After revision, this patient reported no pain and no activity limitations and was satisfied with the procedure. Another hemiarthroplasty was revised to a stem-supported hemiarthroplasty for persistent pain. This implant was not loose at the time of revision; the glenoid appeared normal, and no source of pain could be identified. The patient continued to have pain after revision and was dissatisfied with the procedure. One resurfacing humeral prosthesis was placed on an insufficient humeral head. The patient was satisfied initially and continued to be highly active for 2 years; however, the prosthesis became loose, requiring revision to a stemmed prosthesis, after which the patient resumed high activity levels and was pain free (Fig. 3). Another hemiarthroplasty was revised to a total resurfacing prosthesis by the addition of a glenoid prosthesis. This patient was highly active and satisfied after revision surgery. Two loose polyethylene glenoid prostheses were removed and one was revised; all three patients reported a satisfactory outcome and had no limitations after their index procedure for 3 to 5 years before pain developed. All 3 were satisfied and had no activity limitations after their revision procedures. One loose glenoid prosthesis was painful, but the patient did not elect to undergo revision surgery. Seven patients were lost to follow-up and are not included in the results.

Discussion

In recent years, shoulder resurfacing has gained favor by surgeons and patients for several reasons. The primary reason is that the humeral head is retained, as opposed to total shoulder arthroplasty, which removes the entire humeral head. In addition, because the head is retained, there is no need to re-create the head/shaft angle.² Treating complications of shoulder arthroplasty may be easier with resurfacing prostheses as compared with stemmed prostheses. For example, treating an infection would be easier with a limited amount of implanted material. If an infection or joint instability occurred, the joint may be amenable to

Table IV Preoperative and postoperative Constant scores

	Preoperatively		Postoperatively		P value
	Hemi-resurfacing	Total resurfacing	Hemi-resurfacing	Total resurfacing	
Constant score (range)	21.4 ± 12.3 (11-33)	19.2 ± 11.2 (8-30)	59.8 ± 16.5 (56-83)	63.7 ± 13.2 (51-85)	≤ .001
Age- and sex-adjusted Constant score (range) (%)	34.6 ± 13.3 (21-47)	30.4 ± 9.1 (18-39)	71.2 ± 30.5 (52-101)	75.2 ± 17.1 (47-109)	≤ .001

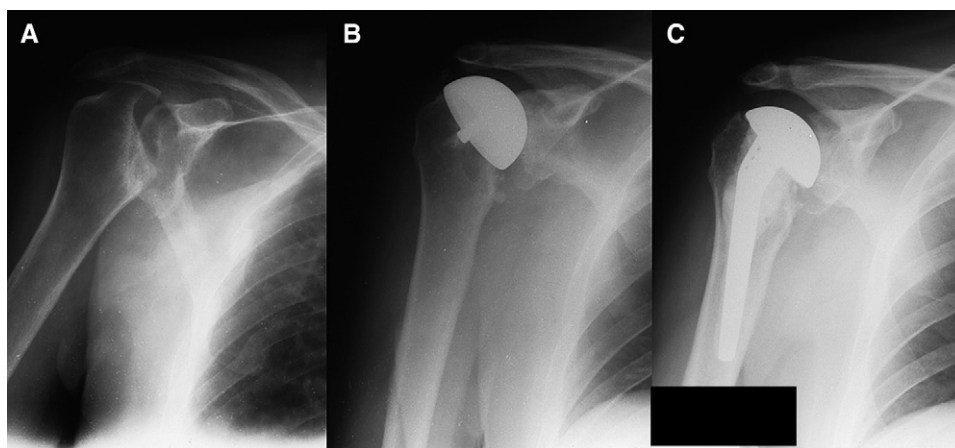


Figure 3 Anteroposterior shoulder radiographs. **A**, Preoperative image with large humeral head defect from anterior dislocation. **B**, Postoperative image after insertion of cemented hemi-resurfacing prosthesis. **C**, Postoperative image after revision of resurfacing prosthesis to cemented stem-supported humeral prosthesis.

arthrodesis, which may not be an option after infection and/or instability with a stemmed shoulder prosthesis. In the event of failure, revision of a humeral prosthesis may be easier when all the proximal humeral bone remains. In addition, periprosthetic fractures may be less common and treated more easily in the resurfaced shoulder as compared with total shoulder arthroplasty with a stem in the intramedullary canal.^{5,15} For the patient, postoperative satisfaction is comparable to that achieved with total shoulder arthroplasty. Patients may enjoy easier postoperative rehabilitation after shoulder resurfacing versus shoulder replacement.^{1,5} There are also theoretic advantages to resurfacing, such as the possibility that proprioceptive feedback is preserved, leading to better function.^{9,15} However, as with any procedure, there may be limitations associated with shoulder resurfacing. It has been suggested that humeral resurfacing prostheses can loosen and fail more commonly over time than stem-supported prostheses because they have less fixation area.^{6,12,23} In addition, there is fear that humeral neck fracture or humeral head collapse may occur in a similar manner to what occurs with hip resurfacing,^{12,20} although the shoulder joint supports lower loads than the hip joint.² In some patients, however, total shoulder resurfacing can be more technically demanding than total shoulder replacement, because access for preparation of the glenoid is more difficult without removal of the humeral head. If there is not enough humeral head remaining, a stemmed device is needed. We and others have

found that if 70% of the humeral head remains based on intraoperative assessment of the surface area, it is adequate to support a resurfacing prosthesis.⁵ Burgess et al² report that in their experience, 60% is sufficient with bone grafting.

Contemporary shoulder resurfacing began again in 1986 with a cementless hydroxyapatite-coated prosthesis.^{5,15,16} At midterm follow-up, the revision rate for this humeral prosthesis is 1% to 2%. When a glenoid prosthesis is used, loosening occurs in up to 10% of patients.^{15,16}

Ninety-five percent of patients report a satisfactory functional outcome with shoulder resurfacing.^{5,14-16} These favorable results are, no doubt, partially because of the ability to obtain correct version, inclination, offset, and size. These factors are judged easily and relate directly to the anatomy. In fracture and replacement cases, the humeral head has been removed and version is estimated either indirectly or from guides during surgery. It is reported that 30% of unsatisfactory results after shoulder replacements are due to component malpositioning.¹⁰

The long-term debate about whether a total arthroplasty or hemiarthroplasty procedure is best is not solved with our work. In stemmed total shoulder replacement, the rate of conversion from a hemiarthroplasty to a total shoulder replacement is up to 12%.⁹ The conversion rate may be less with resurfacing.^{2,5,8} We attribute at least some of the success of our hemi-resurfacing procedures to releasing soft-tissue contractures and restoring the normal humeral

contours.^{2,5} This likely improves the kinematics of shoulder function. Because the version and spacing of the joint are improved, less subsequent glenoid pain and wear may result. This may suggest performing a hemiarthroplasty in many cases.^{2,5,8,11,15,16,25}

The shoulder resurfacing prosthesis in this study achieved its goal of reducing pain and improving function. The patient satisfaction results in our study are as good as or better than those reported with a conventional stemmed humeral prosthesis.^{9,17,18,26} Patient satisfaction in our series was 95%; Levy and Copeland¹⁵ in 2001 reported that 94% of their 94 patients (103 shoulders) felt that the "shoulder was improved." In 2004, they reported that of 71 patients (79 shoulders), 90% of the patients considered the "shoulder to be better."¹⁴ The survival of the humeral prosthesis in our study is very satisfactory, at 96% but in agreement with other studies, we found that the glenoid component remains vulnerable to wear and loosening.^{9,18,26} Among the 41 glenoid components implanted and 38 available for radiographic review, we found radiolucencies in 12 cemented polyethylene glenoid prostheses, yet only 3 required revision. Radiographically, 3 of our polyurethane glenoid prostheses were severely worn, although none was loose or required revision.

There were few complications in our series. There were no instances of subluxation or dislocation. There were no periprosthetic fractures, possibly because of the lack of stress shielding with resurfacing.^{13,19,27} Implant instability is a reported complication of total shoulder replacement.^{17,18,21,22,26} There were 2 cases of humeral prosthesis loosening that required revision (1 was an early-generation cementless prosthesis attached with a bolt through the lateral humeral cortex, a design that we discontinued using after 3 cases). The other humeral prosthesis that became loose was implanted on a deficient humeral head. There were no infections in our series.

There are limitations to this study. The patient population reported is small but, nonetheless, comparable to other published studies of shoulder resurfacing (ie, Steffee and Moore,²⁵ 53 patients; Levy and Copeland,¹⁵ 94 patients; Levy and Copeland,¹⁴ 71 patients; and Bailie et al,¹ 36 patients). Nevertheless, small case numbers suggest caution in interpreting the incidence of uncommon complications, such as periprosthetic fracture and infection. Our study investigates the Total Articular Replacement Arthroplasty prosthesis that was in evolution as it was being implanted. Both cemented and cementless humeral fixations were used, but we are unable to draw conclusions about this variable. There were no autopsy retrievals or pathologic specimens evaluated. Other limitations are that the 2 surgeons involved performed the clinical and radiographic analyses. However, the primary outcome (patient satisfaction of 95%) and the secondary outcome (implant survival of 96%) are known for all but 7 patients who were lost to follow-up. Because this is a single-procedure series, there is no comparison to results of using stemmed humeral

devices, although other investigators have reported essentially equal results with regard to patient satisfaction.^{9,17,18,26} Our study sought to report patient satisfaction and prosthesis survival after shoulder resurfacing.

Total shoulder resurfacing is a valid procedure and, like total shoulder replacement, will result in excellent pain relief and restoration of function. However, the problem of glenoid loosening remains. The difficulties with total shoulder resurfacing are primarily on the glenoid side; well-performed humeral resurfacing rarely fails over time, with or without the use of cement. The results of revision surgery after shoulder resurfacing were generally favorable as well.

Conclusions

The long-term results of stem-supported total shoulder replacement support its use as a reliable procedure for treating degenerative conditions of the glenohumeral joint. Published reports indicate that the procedure provides pain relief and results in implant survivorship of 84% to 96% at 12 years.^{3,24,26} However, shoulder resurfacing is an attractive option for treating shoulder arthritis. It can be used in the treatment of osteoarthritis, rheumatoid arthritis, post-dislocation arthritis, and osteonecrosis.^{5,8,11,15,16} It works well, is bone conserving, and avoids some of the concerns associated with a stem-supported prosthesis. In addition, there are more salvage options in the rare event of a failure. Shoulder resurfacing is a reasonable option for a young, active patient. This study showed that shoulder resurfacing in our patient population resulted in a functional patient satisfaction rate of 95%, with 92% of the patients having no limitations in their activities. The survivorship of the humeral prosthesis was 96% at a minimum 20-year follow-up (mean, 28 years; range, 20-41 years). Moreover, there were few complications in this series of 74 shoulders, and 6 of the 7 revision procedures resulted in a good final outcome.

Acknowledgment

The author acknowledges the late Charles O. Townley, MD, who performed some of the operative procedures included in this study. He died on December 23, 2006. The author acknowledges the editorial assistance of Janet L. Tremaine, ELS, Tremaine Medical Communications, Dublin, Ohio.

Disclaimer

The author, his immediate family, and any research foundation with which he is affiliated did not receive any

financial payments or other benefits from any commercial entity related to the subject of this article. No outside funding or grants were associated with this study.

References

- Bailie SD, Llinas PJ, Ellenbecker TS. Cementless humeral resurfacing arthroplasty in active patients less than fifty-five years of age. *J Bone Joint Surg Am* 2008;90:110-7. doi:10.2106/JBJS.F.01552
- Burgess D, McGrath M, Bonutti P, Marker D, Delanois R, Mont M. Current concepts review: shoulder resurfacing. *J Bone Joint Surg Am* 2009;91:1128-238. doi:10.2106/JBJS.H.01082
- Cofield RH. Total shoulder arthroplasty with the Neer prosthesis. *J Bone Joint Surg Am* 1984;66:899-906.
- Constant C, Murley A. A clinical method of functional assessment of the shoulder. *Clin Orthop Relat Res* 1987;160-4.
- Copeland S. The continuing development of shoulder replacement: "reaching the surface." *J Bone Joint Surg Am* 2006;88:900-5. doi:10.2106/JBJS.F.00024
- Egund N, Jonsson E, Lidgren L, Kelly I, Petterson H. Computed tomography of humeral cup arthroplasties. *Acta Radiol* 1987;28: S71-3. doi:10.3109/02841858709177311
- Franklin JL, Barrett WP, Jackins SE, Matsen FA III. Glenoid loosening in total shoulder arthroplasty. Association with rotator cuff deficiency. *J Arthroplasty* 1988;3:39-60. doi:10.1016/S0883-5403(88)80051-2
- Furst M, Fink B, Ruther W. The DUROM cup humeral surface replacement in patients with rheumatoid arthritis. *J Bone Joint Surg Am* 2007;89:1756-62. doi:10.2106/JBJS.F.01290
- Gartsman GM, Roddey TS, Hammerman SM. Shoulder arthroplasty with or without resurfacing of the glenoid in patients who have osteoarthritis. *J Bone Joint Surg Am* 2000;82:26-34.
- Hasan SS, Leith JM, Campbell B, Kapil R, Smith KL, Matsen FA III. Characteristics of unsatisfactory shoulder arthroplasties. *J Shoulder Elbow Surg* 2002;11:432-41. doi:1067/mse.2002.125806
- Johnson E, Egund N, Kelly I, Rydholm U, Lidgren L. Cup arthroplasty of the rheumatoid shoulder. *Acta Orthop Scand* 1986; 57:542-6. doi:10.3109/17453678609014790
- Jónsson E, Lidgren L, Mjöberg B, Rydholm U, Selvic G. Humeral cup fixation in rheumatoid shoulders. *Acta Orthop Scand* 1990;61:116-7.
- Kumar S, Sperling JW, Haidukewych GH, Cofield RH. Periprosthetic humeral fractures after shoulder arthroplasty. *J Bone Joint Surg Am* 2004;86:680-9.
- Levy O, Copeland SA. Cementless surface replacement arthroplasty (Copeland CSRA) for osteoarthritis of the shoulder. *J Shoulder Elbow Surg* 2004;13:266-71. doi:10.1016/j.jse.2004.01005
- Levy O, Copeland SA. Cementless surface replacement arthroplasty of the shoulder. 5- to 10-year results with the Copeland Mark-2 prosthesis. *J Bone Joint Surg Br* 2001;83:213-21. doi:10/1302/0301-620X.83B2.11238
- Levy O, Funk L, Sforza G, Copeland SA. Copeland surface replacement arthroplasty of the shoulder in rheumatoid arthritis. *J Bone Joint Surg Am* 2004;86:512-8.
- Neer CS. Articular replacement for the humeral head. *J Bone Joint Surg Am* 1955;37:215-28.
- Neer CS, Watson KC, Stanton FJ. Recent experience in total shoulder replacement. *J Bone Joint Surg Am* 1982;64:319-37.
- Orr TE, Carter DR. Stress analysis of joint arthroplasty in the proximal humerus. *J Orthop Res* 1985;3:360-71. doi:10.1002/jor.1100030313
- Pritchett JW. Curved-stem hip resurfacing—minimum 20-year follow-up. *Clin Orthop Relat Res* 2008;466:1177-85. doi:10.1007/S11999-008-0165-2
- Pritchett JW. Inferior subluxation of the humeral head after trauma or surgery. *J Shoulder Elbow Surg* 1997;6:356-9. doi:10.1016/S1058-2746(97)90003-3
- Pritchett JW, Clark JM. Prosthetic replacement for chronic unreduced dislocations of the shoulder. *Clin Orthop Relat Res* 1987;89-93.
- Rydholm U. Surface replacement of the humeral head in rheumatoid shoulder. *J Shoulder Elbow Surg* 1993;2:286-95. doi:10.1016/1058-2746(93)90074-Q
- Settegren CR. Total shoulder arthroplasty with the Neer prosthesis: long term results. *J Shoulder Elbow Surg* 1997;6:495-505.
- Steffee AD, Moore RW. Hemi-resurfacing arthroplasty of the shoulder. *Contemp Orthop* 1984;9:51-9.
- Torchia ME, Cofield RH, Settegren CR. Total shoulder arthroplasty with the Neer prosthesis: long-term results. *J Shoulder Elbow Surg* 1997;6:495-505. doi:10.1016/S1058-2746(97)90081-1
- Walker PS. Some bioengineering considerations of prosthetic replacement for the glenohumeral joint. In: English AE, editor. *Symposium on the total joint replacement of the upper extremity*. St Louis: Mosby; 1975. p. 25-32.
- Weiss AP, Adams MA, Moore JR, Weiland AJ. Unconstrained shoulder arthroplasty; a five-year average follow-up study. *Clin Orthop Relat Res* 1990;86-90.
- Zippel J. Dislocation-proof shoulder prosthesis model BME [in German]. *Z Orthop Ihre Grenzgeb* 1975;113:454-7.